



Delivering Point-of-Care ultrasound teaching using a video conferencing technique

Enseignement de l'échographie au chevet à l'aide d'une technique de visioconférence

Evan Tang , Ryan Daniel , Lauren Wintraub, Matthew W Nelms, Claire Heslop , Dennis Dane Cho  et Mirek Otremba

Volume 14, numéro 6, 2023

URI : <https://id.erudit.org/iderudit/1108933ar>
DOI : <https://doi.org/10.36834/cmej.76285>

[Aller au sommaire du numéro](#)

Éditeur(s)

Canadian Medical Education Journal

ISSN

1923-1202 (numérique)

[Découvrir la revue](#)

Citer cet article

Tang, E., Daniel, R., Wintraub, L., Nelms, M., Heslop, C., Cho, D. & Otremba, M. (2023). Delivering Point-of-Care ultrasound teaching using a video conferencing technique. *Canadian Medical Education Journal / Revue canadienne de l'éducation médicale*, 14(6), 118–121. <https://doi.org/10.36834/cmej.76285>

Résumé de l'article

Énoncé des implications de la recherche

L'échographie au chevet fait généralement l'objet d'un enseignement pratique, en personne. Nous présentons une nouvelle approche, virtuelle, pour son enseignement, par visioconférence à double flux vidéo. L'approche que nous décrivons est facile à mettre en œuvre. Nous résumons l'expérience et les commentaires des étudiants en médecine sur cette modalité qui est susceptible d'améliorer l'enseignement dans des contextes où les ressources sont limitées ou en cas de pandémie, lorsque l'approche pratique n'est pas possible.

© Evan Tang, Ryan Daniel, Lauren Wintraub, Matthew W Nelms, Claire Heslop, Dennis Dane Cho, Mirek Otremba, 2023



Ce document est protégé par la loi sur le droit d'auteur. L'utilisation des services d'Érudit (y compris la reproduction) est assujettie à sa politique d'utilisation que vous pouvez consulter en ligne.

<https://apropos.erudit.org/fr/usagers/politique-dutilisation/>

Érudit

Cet article est diffusé et préservé par Érudit.

Érudit est un consortium interuniversitaire sans but lucratif composé de l'Université de Montréal, l'Université Laval et l'Université du Québec à Montréal. Il a pour mission la promotion et la valorisation de la recherche.

<https://www.erudit.org/fr/>

Delivering Point-of-Care ultrasound teaching using a video conferencing technique

Enseignement de l'échographie au chevet à l'aide d'une technique de visioconférence

Evan Tang,¹ Ryan Daniel,¹ Lauren Wintraub,¹ Matthew W Nelms,¹ Claire Heslop,^{1,2} Dennis Dane Cho,^{1,2} Mirek Otremba^{1,3}

¹Temerty Faculty of Medicine, University of Toronto, Ontario, Canada; ²Division of Emergency Medicine, Department of Medicine, University of Toronto, Ontario, Canada; ³Department of Medicine, Royal Jubilee Hospital, British Columbia, Canada

Correspondence to: Evan Tang; evan.tang@mail.utoronto.ca

Edited by: Marcel D'Eon (editor-in-chief)

Published ahead of issue: Sept 12, 2023; published: Dec 30, 2023. CMEJ 2023, 14(6). Available at <https://doi.org/10.36834/cmej.76285>

© 2023 Tang, Daniel, Wintraub, Nelms, Heslop, Cho, Otremba; licensee Synergies Partners. This is an Open Journal Systems article distributed under the terms of the Creative Commons Attribution License. (<https://creativecommons.org/licenses/by-nc-nd/4.0>) which permits unrestricted use, distribution, and reproduction in any medium, provided the original work is cited.

Implication Statement

Point-of-care ultrasound (POCUS) has usually been taught using a hands-on, in-person approach. We present a novel approach to delivering POCUS virtually using a dual image videoconferencing technique. We outline an easily implementable approach and summarize medical students' experience and feedback. This form of delivery has potential to improve instructional delivery in resource restricted settings or during pandemic restrictions where a hands-on approach may not be possible.

Énoncé des implications de la recherche

L'échographie au chevet fait généralement l'objet d'un enseignement pratique, en personne. Nous présentons une nouvelle approche, virtuelle, pour son enseignement, par visioconférence à double flux vidéo. L'approche que nous décrivons est facile à mettre en œuvre. Nous résumons l'expérience et les commentaires des étudiants en médecine sur cette modalité qui est susceptible d'améliorer l'enseignement dans des contextes où les ressources sont limitées ou en cas de pandémie, lorsque l'approche pratique n'est pas possible.

Introduction

Point-of-care ultrasound (POCUS) is becoming a mainstay in healthcare with a growing number of applications. Both medical knowledge and psychomotor skills for image acquisition are needed. POCUS has usually been taught through a combination of lectures and hands-on learning. The hands-on component allows trainees to develop the psychomotor skills necessary for image acquisition. However, it is unclear whether the hands-on component can be taught successfully without in-person guidance.¹ Due to infection concerns, hands-on learning had not been possible during the COVID-19 pandemic. In-person lectures, web-based lectures, and self-directed learning from asynchronous educational videos are alternative modalities being used to teach POCUS but have been unable to completely replicate the hands-on experience.^{2,3}

Telesimulation has been used to provide procedural training in areas such as laparoscopic training, interosseus needle insertion, and ultrasound-guided regional anesthesia.⁴ However, its utility in providing ultrasound training for novice learners has not been explored. We describe an approach to delivering virtual POCUS teaching to novice learners which fills the gap between lectures and hands-on learning to improve the psychomotor image acquisition skills where in-person sessions are not feasible.

Approach to delivery of ultrasound scanning session

A dual-view approach was implemented, where participants simultaneously observe the placement of the ultrasound probe from a first person-view and the ultrasound image output (Figure 1). We are happy to share

how we were able to achieve this. The session begins with an overview of ultrasound fundamentals, including the technology. The instructor provides an overview of relevant anatomy using the ultrasound while interacting with participants by responding to inquiries in real-time. This is followed by a narrative demonstration of the scan, with a discussion on how to optimize the view and how different movements of the ultrasound probe reflect changes in the acquired image. This approach aims to replicate what students would observe while completing in-person workshops. The ability to simultaneously demonstrate ultrasound probe positioning and the acquired image using virtual livestream technology is a novel educational approach.

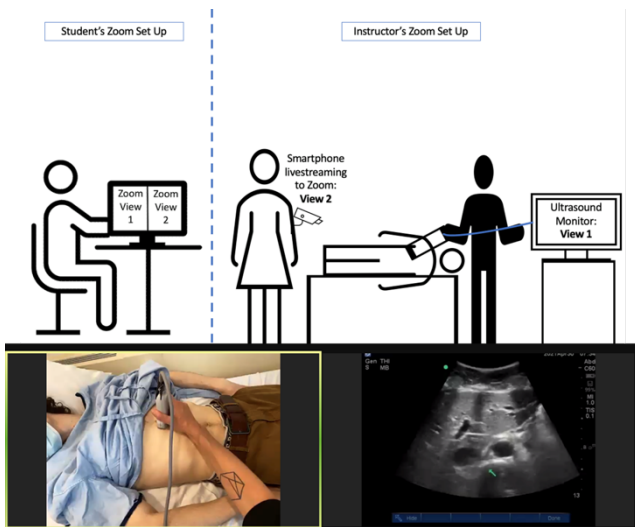


Figure 1. Overview of Live-Stream setup with sample screenshot illustrating the dual-view setup

Outcomes

We piloted this pedagogy with a group of 10 student volunteers and collected anonymous post-session evaluation (Appendix A). Six (60%) of the participants responded, with all respondents strongly agreeing or agreeing that their knowledge improved and that they felt engaged. Half of the respondents agreed that this approach allowed visualization of the technique with the other respondents reported being neutral ($n = 2$) or disagreeing ($n = 1$). Results were presented to faculty and thus garnered support for a broader implementation to the curriculum.

Our faculty scheduled within the curriculum a session on ultrasound basics, focused on assessment with sonography in trauma, and abdominal aorta ultrasound for a class of 134 medical students. No substantial pedagogical changes were made based on the feedback from the pilot session.

Twenty-three (17%) students completed the post-session survey. All students ($n = 23$) strongly agreed or agreed that the objectives of the session were achieved (Appendix B). In addition, 87% ($n = 20$) of respondents strongly agreed or agreed that this approach allowed visualization of the ultrasound maneuvers.

REB approval was waived by the University of Toronto REB as this was a quality improvement initiative.

Discussion and next steps

This initiative demonstrates the feasibility of a videoconferencing-based approach to teaching early POCUS skills for novice ultrasound users. This has potential application for virtual learning, whether it be for undergraduate medical education or for training practitioners in rural and resource restricted settings, where access to in-person training is a barrier.^{2,5} The dual-video livestream provides learners with real time visualization of image acquisition and ultrasound output, possibly augmenting the development of the necessary psychomotor skills. The results of this work are limited by the single cohort nature of this data in a quality improvement context and continued study is needed.

Next steps will include controlled studies between traditional in-person instruction and this novel pedagogy using objective, competency-based endpoints.

Conflicts of Interest: None Declared

Funding: This initiative received no specific grant from any funding agency in the public, commercial, or not-for-profit sectors.

References

1. Damewood SC, Leo M, Bailitz J, et al. Tools for measuring clinical ultrasound competency: recommendations from the ultrasound competency work group. *AEM Educ Train.* 2019;4(1):106-S112. <https://doi.org/10.1002/aet2.10368>
2. Moses A, Weng W, Orchanian-Cheff A, Cavalcanti RB. Teaching point-of-care ultrasound in medicine. *Can J Gen Intern Med.* 2020; 15(2):13-29. <https://doi.org/10.22374/cjgim.v15i2.368>
3. Goldsmith AJ, Eke OF, Alhassan Al Saud A, et al. Remodeling point-of-care ultrasound education in the era of COVID-19. *AEM Educ Train.* 2020; 4(3):321-324 <https://doi.org/10.1002/aet2.10475>
4. McCoy CE, Sayegh J, Alrabah R, et al. Telesimulation: an innovative tool for health professions education. *AEM Educ Train.* 2017;1(2):132-136. <https://doi.org/10.1002/aet2.10015>

5. Micks T, Sue K, Rogers P. Barriers to point-of-care ultrasound use in rural emergency departments. *Can J Emerg Med.* 2016; 18(6):475-479. <https://doi.org/10.1017/cem.2016.337>

Appendix A. Post-session evaluation

The objectives of the workshop/seminar were clear					
	1	2	3	4	5
Strongly Agree	<input type="radio"/>	<input type="radio"/>	<input type="radio"/>	<input type="radio"/>	<input type="radio"/>
					Strongly Disagree
The materials used for the workshop/seminar (cases, references, etc.) were helpful					
	1	2	3	4	5
Strongly Agree	<input type="radio"/>	<input type="radio"/>	<input type="radio"/>	<input type="radio"/>	<input type="radio"/>
					Strongly Disagree
The objectives of the workshop/seminar were achieved					
	1	2	3	4	5
Strongly Agree	<input type="radio"/>	<input type="radio"/>	<input type="radio"/>	<input type="radio"/>	<input type="radio"/>
					Strongly Disagree
I was able to effectively visualize the ultrasound maneuvers performed in this teaching session					
	1	2	3	4	5
Strongly Agree	<input type="radio"/>	<input type="radio"/>	<input type="radio"/>	<input type="radio"/>	<input type="radio"/>
					Strongly Disagree
The online format did not impede my knowledge gain from this learning experience					
	1	2	3	4	5
Strongly Agree	<input type="radio"/>	<input type="radio"/>	<input type="radio"/>	<input type="radio"/>	<input type="radio"/>
					Strongly Disagree
The instructor was knowledgeable and well prepared					
	1	2	3	4	5
Strongly Agree	<input type="radio"/>	<input type="radio"/>	<input type="radio"/>	<input type="radio"/>	<input type="radio"/>
					Strongly Disagree
The instructor stimulated enthusiasm in learning the topic					
	1	2	3	4	5
Strongly Agree	<input type="radio"/>	<input type="radio"/>	<input type="radio"/>	<input type="radio"/>	<input type="radio"/>
					Strongly Disagree
The instructor provided clear explanations					
	1	2	3	4	5
Strongly Agree	<input type="radio"/>	<input type="radio"/>	<input type="radio"/>	<input type="radio"/>	<input type="radio"/>
					Strongly Disagree

Appendix B. Session outline and objectives

Learning objectives:

- Describe the role of POCUS to augment physical examination when looking for free fluid in the chest and abdomen
- Recognize the ultrasound appearance of a pleural effusion and free intra-abdominal fluid

Topics covered:

1. General principles of POCUS
 - a. Optimization of images (depth/gain)
 - b. Probe selection
 - c. Standard imaging convention including probe indicator direction and various planes that are used in ultrasound imaging
 - d. Use of color doppler in assessment of vascular structures
2. Abdomen/FAST protocol (Focused Assessment with Sonography for Trauma)
 - i. Probe selection
 - ii. Demonstration of search for free fluid using the FAST technique
 1. RUQ – Hepatorenal
 - a. Understanding Anatomy
 - i. Diaphragm
 - ii. Liver
 - iii. Kidney
 - iv. Hepatorenal recess (Morrison’s pouch)
 - v. Spine
 2. LUQ – Splenorenal
 - a. Understanding Anatomy
 - i. Diaphragm
 - ii. Spleen
 - iii. Kidney
 - iv. Hepatorenal recess
 - v. Spine
 3. Cardiac – Subxiphoid
 - a. Understanding Anatomy
 - i. Liver
 - ii. Pericardium
 - iii. LV/RV
 4. Suprapubic
 - a. Understanding Anatomy
 - i. Bladder
 - ii. Uterus/Prostate
3. Aorta
 - a. Visualize the abdominal aorta in transverse and longitudinal views
 - b. Scan the length of the aorta from upper abdomen to iliac bifurcation
 - c. Measure the aorta (transverse & AP diameters). Understand the measurements for normal and abnormal aorta diameters (i.e. AAA)
 - d. Understanding of abdominal anatomy to aid in physical examination of the aorta
 - i. Relationship to
 1. Liver
 2. IVC
 3. Spine